



# Embolization of Bleeding Ileal Varices post Adnexal Biopsy in Liver Cirrhosis without Gastroesophageal Varices

Suhas D. Wagle<sup>1</sup>  Yadav Munde<sup>2</sup> Smita Kori Vaze<sup>3</sup> Tejas Mankeshwar<sup>3</sup>

<sup>1</sup>Gastroenterology Unit, Department of Medicine, King Edward Memorial Hospital, Pune, Maharashtra, India

<sup>2</sup>Department of Interventional Radiology, King Edward Memorial Hospital, Pune, Maharashtra, India

<sup>3</sup>Department of Radiodiagnosis and Imaging, King Edward Memorial Hospital, Pune, Maharashtra, India

Address for correspondence Suhas D. Wagle, MD, Department of Medicine, King Edward Memorial Hospital, 489, Rasta Peth, Sardar Moodliar Road, Pune 411011, Maharashtra, India (e-mail: swagle@kemhospital.org).

J Clin Interv Radiol ISVIR 2024;8:202–204.

## Abstract

### Keywords

- ▶ ectopic
- ▶ glue
- ▶ coil

Bleeding ileal varices are rare in liver cirrhosis, where the gastroesophageal varices frequently accompany ectopic varices. Small bowel varices usually develop in patients with a history of abdominal surgery. We report a case of bleeding ileal varices without accompanying gastroesophageal varices, managed by percutaneous embolization, in a case of liver cirrhosis with no history of laparotomy. Computed tomography–guided percutaneous adnexal biopsy had been undertaken a year before the onset of bleeding.

## Introduction

Ectopic varices account for 1 to 5% and 20 to 30%<sup>1</sup> of clinically detected variceal bleeding in intrahepatic and extrahepatic portal hypertension, respectively. Small intestinal varices present with hematochezia without hematemesis in patients with previous abdominal surgery.<sup>2</sup> Clinical management of the small bowel varices is challenging due to the delay in detection, and limited accessibility at routine endoscopy. Anatomical details are vital in planning the approach to management. The outflow of small bowel varices is more commonly seen through the gonadal veins, and less commonly through the internal iliac veins.<sup>3</sup> Vascular intervention to obliterate these varices plays a major role in the management.

## Case Report

A 59-year-old lady, with type 2 diabetes mellitus, hypertension, and hypothyroidism on medications presented with acute hematochezia for 4 days. Three blood transfusions were administered in her hometown before she was referred to our center. Clinically the patient presented with pallor, heart rate of 106/

min, blood pressure of 120/70 mm Hg, and a postural drop in the blood pressure of 18 mm Hg, with no clinical evidence of chronic liver disease. Laboratory parameters included the following: hemoglobin 8.1 g%, total leukocyte count 5520/mm<sup>3</sup>, platelets 105 × 10<sup>3</sup> mm<sup>3</sup>, international normalized ratio (INR) 1.07, total bilirubin 0.5 mg%, aspartate aminotransferase 50 IU/mL, alanine aminotransferase 29 IU/mL, alkaline phosphatase 81 IU/mL, albumin 2.8 g%, globulin 4 g%, and creatinine 0.9 mg%. The viral markers (hepatitis B and C) and the serological tests for autoimmune liver disease were negative. The patient had presented to a gynecologist a year ago with right iliac fossa pain and anorexia. Splenomegaly, cholelithiasis, and bilateral adnexal cystic masses with inflammatory pelvic collection had been reported on ultrasonography. She underwent computed tomography (CT) guided right adnexal biopsy—ovary with suppurative inflammation as per the histopathology report—and had a laparoscopic tubal ligation 30 years back. There was no history of exploratory laparotomy. On admission, a nasogastric tube was placed for gastric lavage, and the aspirate was bloodless. Packed red blood cells were transfused and bowel preparation was undertaken. Hematochezia had ceased with

article published online  
September 19, 2024

DOI <https://doi.org/10.1055/s-0044-1789282>.  
ISSN 2457-0214.

© 2024. The Author(s).

This is an open access article published by Thieme under the terms of the Creative Commons Attribution License, permitting unrestricted use, distribution, and reproduction so long as the original work is properly cited. (<https://creativecommons.org/licenses/by/4.0/>)  
Thieme Medical and Scientific Publishers Pvt. Ltd., A-12, 2nd Floor, Sector 2, Noida-201301 UP, India

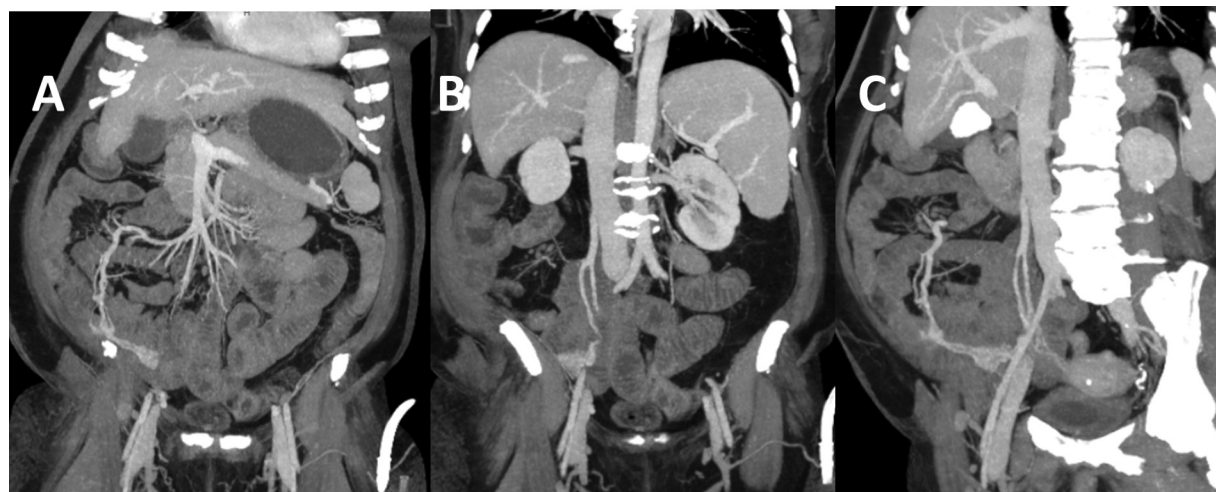
conservative management, and she underwent gastroduodenoscopy and colonoscopy. No upper gastrointestinal abnormality was detected, and varices were absent. Small rectal varices, diminutive rectal polyp, and nonbleeding diverticula in the proximal colon were observed. No blood was encountered up to the proximal duodenum, in the colon and distal ileum. Coarse hepatic echotexture without ascites, splenomegaly, the portal vein of 12 mm, and incidental cholelithiasis were reported on ultrasonography. The patient was deemed to have nonalcoholic fatty liver disease (NAFLD) and was stratified to Child–Pugh–Turcotte (CPT) grade A6 as per the calculated score comprising parameters of ascites, encephalopathy, serum bilirubin, albumin, and prothrombin time. Further, a detailed workup and investigations were pending the patient's approval.

The lady got readmitted after 3 months with acute hematochezia. She had a heart rate of 118/min and blood pressure of 100/70 mm Hg. Hemoglobin levels had dropped to 5.7 g% (from 7.1 g%) along with a drop in hematocrit to 16.5% (from 21.5%) and a dropping platelet count ( $73 \times 10^3/\text{mm}^3$ ). Two units of packed red blood cells and four bags of random donor platelets were transfused along with octreotide infusion. Gastrointestinal endoscopies were repeated after bowel preparation. There was no evidence of varices or bleeding in the upper gastrointestinal endoscopy. Mixed blood residue was encountered in the colon and the distal ileum, suggesting an obscure small bowel source of bleeding. Thereafter, on the CT enteroclysis with mesenteric angiography study (► Fig. 1), ileal varices draining into the inferior vena cava via the right ovarian vein were detected in the portal venous phase. The portal vein size was 16 mm, the umbilical vein had recanalized, and collaterals were seen in the right iliac fossa. The superior mesenteric venogram was undertaken through the left portal vein via a percutaneous transhepatic route. A 6-Fr sheath was placed in the liver and with the help of 4-Fr Cobra catheter and 2.7-Fr Progreate catheter, the varices were cannulated. Contrast injection revealed ileocolic veins retrogradely filling up the ileal varices and draining into the inferior vena cava via the right ovarian vein (► Fig. 2A). All the ileal varices did not get obliterated during the initial attempt at embolization with 20% n-butyl cyanoacrylate (Endocryl, Samarth Lifesciences

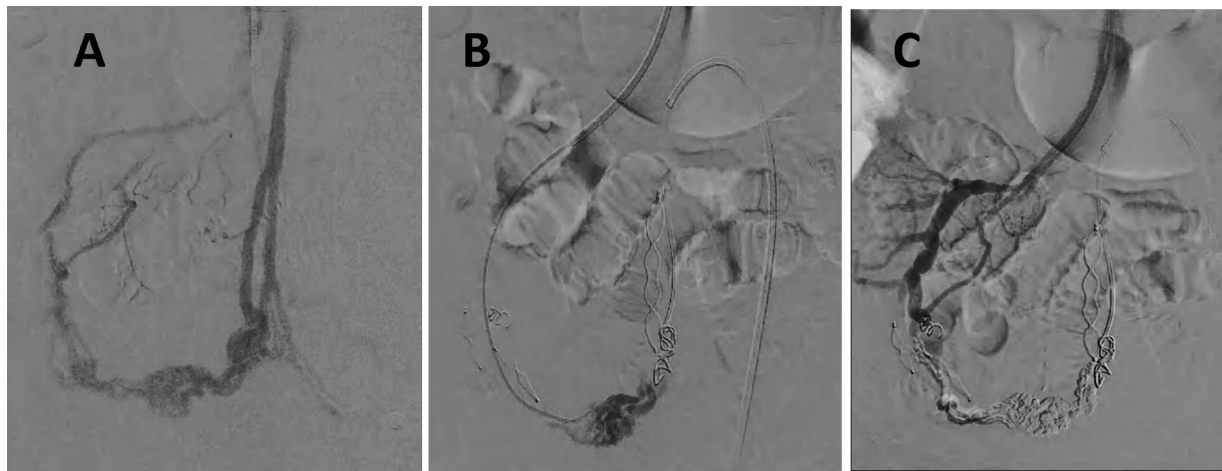
Pvt. Ltd., India). The outflow veins, accessed via the right common femoral vein (► Fig. 2B), were then occluded by 14-mm Amplatzer Vascular Plug 2 (AVP-2; Abbott Medical, Plymouth, MN, United States) and 7 mm  $\times$  100 mm Nester Coil (Cook Medical, Bloomington, IN, United States). Gelfoam (Abgel, Shri Gopalkrishna Labs. Pvt. Ltd, India) and n-butyl cyanoacrylate were re-infused antegradely to obliterate the ileal varices, followed by blocking of the inflow veins with coils. The subsequent superior mesenteric venogram (► Fig. 2C) showed total obliteration of the varices. The access site was closed by 33% glue instilled via a 4-Fr Cobra catheter through the sheath under fluoroscopic and ultrasound guidance. She had an uneventful clinical recovery. On telephonic follow-up after 13 months, she was asymptomatic without gastrointestinal rebleed.

## Discussion

There are no standard guidelines in the management of bleeding ectopic varices.<sup>1</sup> In a review on ectopic varices, Tranah et al<sup>4</sup> recommend an algorithm-based approach in the management. Medications (octreotide, nonselective  $\beta$  blockers), endoscopy-guided sclerotherapy/glue injection, vascular intervention (percutaneous embolization, balloon occluded retrograde transvenous obliteration [BRTO]), transjugular intrahepatic portosystemic shunt (TIPS), and surgery (devascularization, selective portosystemic shunts with or without bowel resection) are the various treatment options.<sup>1,4–6</sup> Due to the underlying chronic liver disease, the role of surgery may be limited to a select few patients for emergency salvage, or in those unresponsive to the nonsurgical therapies. Rebleeding rates up to 20% have been reported after percutaneous embolization in a small case series.<sup>7</sup> In patients with rebleeds and occlusive type of extrahepatic portal hypertension, BRTO and surgery are the second-line therapies.<sup>4</sup> The risk of rebleeds in intrahepatic portal hypertension depends on the severity of underlying chronic liver disease. Selective surgical shunts in Child A cirrhosis<sup>1</sup> and TIPS in advanced cirrhosis,<sup>5</sup> as a bridging procedure to liver transplantation, are options after rebleed. Superior mesenteric vein thrombosis has been an ascribed cause of stand-alone



**Fig. 1** Computed tomography (CT) scan images. (A) Portovenous phase: The filling of ileal varices communicating with the superior mesenteric vein (SMV). (B) The varices draining into the right ovarian vein and inferior vena cava (IVC). (C) The SMV filling the ileal varices that drain into the IVC.



**Fig. 2** Percutaneous embolization. (A) Afferent and efferent tracts of ileal varices. (B) Variceal outflow closed by 14 mm Amplatzer Vascular Plug 2 (AVP-2) and 7 mm × 100 mm Nester coil. (C) Varices completely obliterated and excluded from circulation.

ileal varices.<sup>8</sup> In severe portal hypertension, acute gastrointestinal bleed is a rare manifestation of portal hypertensive gastropathy (2–12%) and colopathy (5%)<sup>9</sup> to be considered in the differential diagnosis.

In our patient with silent chronic liver disease, the absence of gastroesophageal varices was misleading for the diagnosis of ectopic variceal bleed. The ileal varices were obliterated by percutaneous embolization. Probably the inflammatory right adnexal mass, or its CT-guided percutaneous needle biopsy, led to the formation of ileal varices. Past intervention in the pelvis has been recognized as a risk factor for ectopic ileal varices.<sup>10</sup>

## Conclusion

In patients of liver cirrhosis, bleeding ileal varices are rare but merit a high index of suspicion in obscure gastrointestinal bleeding. Transabdominal needle biopsies of inflammatory adnexal masses may have a role in the formation of ectopic varices. Obliteration of the bleeding ileal varices by vascular intervention would be a preferred option over surgery, if these varices are not accessible at endoscopy.

### Author Contributions

S.D.W. contributed to clinical investigation, conceptualization, writing the original draft, visualization, literature review, and references. Y.M. contributed to clinical investigation, writing, review, editing, literature review, and references. S.K.V. and T.M. contributed to clinical investigation, writing, review, and editing.

### Disclosures

To date, the case has neither been reported nor presented in any meeting or forums.

### Ethical Approval

This study was formally approved by the KEM Hospital Research Centre Ethics Committee.

### Informed Consent

Written informed consent for publication was obtained from the patient/close relative.

### Funding

None.

### Conflict of Interest

None declared.

## References

- 1 Sarin SK, Kumar CKN. Ectopic varices. *Clin Liver Dis* (Hoboken) 2012;1(05):167–172
- 2 Cappell MS, Price JB. Characterization of the syndrome of small and large intestinal variceal bleeding. *Dig Dis Sci* 1987;32(04):422–427
- 3 Akhter NM, Haskal ZJ. Diagnosis and management of ectopic varices. *Gastrointest Interv* 2012;1(01):3–10
- 4 Tranah TH, Nayagam JS, Gregory S, et al. Diagnosis and management of ectopic varices in portal hypertension. *Lancet Gastroenterol Hepatol* 2023;8(11):1046–1056
- 5 Sato T. Treatment of ectopic varices with portal hypertension. *World J Hepatol* 2015;7(12):1601–1605
- 6 Ohs Z, Jones M, Sharma N, Loveridge K. Percutaneous transhepatic embolization of ectopic varices in a patient with portal hypertension presenting with hemorrhagic shock. *Cureus* 2021;13(09):e18209
- 7 Nadeem IM, Badar Z, Giglio V, Stella SF, Markose G, Nair S. Embolization of parastomal and small bowel ectopic varices utilizing a transhepatic antegrade approach: a case series. *Acta Radiol Open* 2022;11(07):20584601221112618
- 8 Garcia MC, Ahlenstiel G, Mahajan H, van der Poorten D. Small bowel varices secondary to chronic superior mesenteric vein thrombosis in a patient with heterozygous factor V Leiden mutation: a case report. *J Med Case Rep* 2015;9(01):210
- 9 Urrunaga NH, Rockey DC. Portal hypertensive gastropathy and colopathy. *Clin Liver Dis* 2014;18(02):389–406
- 10 Cingel M, Benko J, Samoř M, Mokáň M. Recurrent ileal variceal bleeding as a diagnostic and therapeutic challenge. *Case Rep Gastrointest Med* 2022;2022:7072961