

Water Puppy Syndrome- A Cause for Dystocia in a Labrador Bitch and its Surgical Management

B.R. Suchitra*, S. Rashmi, H.J. Nanditha, N Murthy, P. Prasanna and G. J. Renukaradhya

¹Department of VGO, Veterinary College, Hebbal, Bengaluru-560 024.

[Received: 10.07.2019; Accepted: 12.02.2022]

{DOI 10.29005/IJCP.2022.14.1.20-21}

ABSTRACT

A five year old female Labrador bitch was presented to the clinics of Veterinary Gynaecology and Obstetrics department, Veterinary College, Hebbal, Bengaluru with the history of mating 67 days before and delivery of one live pup about 12 hours before. On abdominal palpation, fetal parts were palpable. Transabdominal ultrasonography revealed presence of a viable oversized anasarca fetus which has heart rate around 224 bpm. The bitch was subjected to caesarean operation under general anaesthesia and a large anasarca live fetus was removed. Surgical wound was sutured and post operative medications were given for seven days along with wound dressing on alternate days. The bitch was recovered uneventfully.

Key words: Water puppy, Dystocia, Ultrasonography, Surgical management

INTRODUCTION

Fetal anasarca, also known as water puppies or walrus puppies, is characterized by congenital oedema and excessive accumulation of subcutaneous fluids, with or without visceral effusions (Cunto *et al.*, 2015). Water puppies can be 2 to 4 times larger than normal pups in the litter and often causes dystocia. Water puppy syndrome can affect only one or two puppies, or even the entire litter. This condition is a potentially fatal and commonly found in short-nosed dog breeds such as Bulldogs, French Bulldogs, Boston Terrier, Pugs, Labrador Retrievers and Yorkshire Terriers (Hopper *et al.*, 2004; Hoskins, 2008).

CASE HISTORY

A five year old primiparous Labrador bitch was presented to the Veterinary Gynaecology and Obstetrics Clinics, Veterinary College, Hebbal, Bengaluru with the history of animal being mated 67 days before and has delivered one live pup about 12 hours before. On abdominal palpation largely distended gravid uterus and fetal parts were palpable. Ultrasonographic examination revealed presence of over-sized viable foetus of approximately 57.0 ± 2 days (Fig. 1). The fetal heart rate was around 224 beats per minute. The affected fetus showed fluid accumulation between the skin and subcutaneous tissue. The case was diagnosed as dystocia due to fetal anasarca and presented for caesarean operation.

TREATMENT

The animal was prepared aseptically for mid

ventral caesarean section under general anaesthesia using 1% Propofol® @ 4-6 mg/kg. The distended gravid uterus was exteriorized and an oversized live water puppy was removed from the right uterine horn. The puppy had visceroptosis of thoracic and abdominal cavity (Fig. 2). Considering, the degree of uterine enlargement and no requirement of future breeding, ovario-hysterectomy was also performed. Both the ovaries along with broad ligaments were

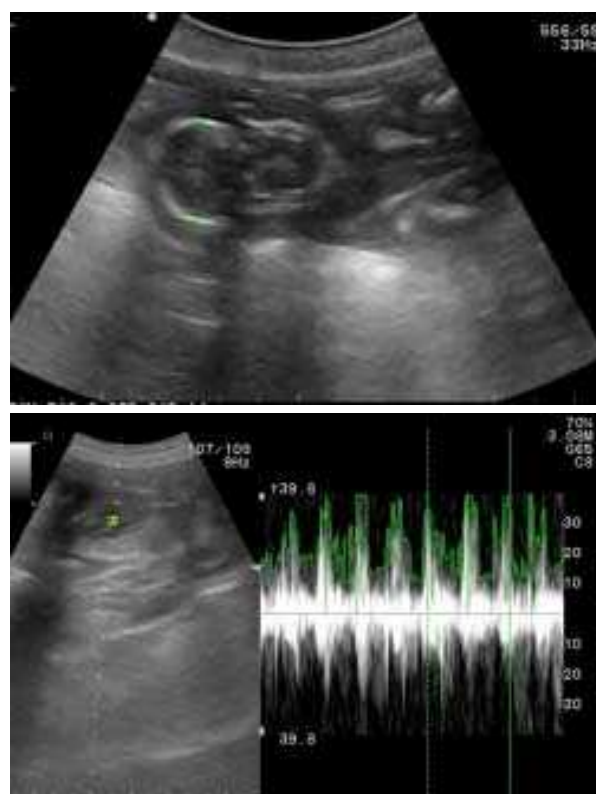


Fig. 1: Ultrasonography of the anasarca puppy

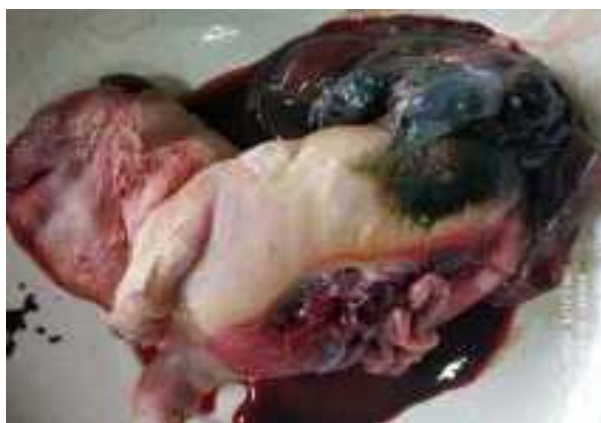

Fig. 2: Gigantic water puppy with visceroptosis of thoracic and abdominal cavity

ligated separately using Catgut no. 1 and severed. The cervical end of the uterus was ligated and transfixed using Catgut no. 1 and dissected. The incised muscle and peritoneum were sutured using Vicryl® no. 0 by continuous interlocking pattern. Suturing of subcutaneous tissue was done using Vicryl® No. 0 by simple continuous pattern and the skin incision was closed using Trulon® No. 0 by cross mattress suturing pattern. Post operative antibiotic using Sporidex® @ 20-25 mg/kg B.W. bid was administered for 7 days alongwith alternate days wound dressing. The animal had uneventful recovery and the skin sutures were removed on day 10 post operation.

DISCUSSION

Imbalance in the homeostasis of the fetal fluids is considered as the cause of fetal anasarca (Lumbers *et al.*, 2001), nevertheless the precise etiology is not

known. Hopper *et al.* (2004). The parity of bitch is considered as an important risk factor, since it involves more frequently in the litters of primiparous bitch. The oedematous pup was frequently the sole occupant of uterine horn and often results in dystocia (Ladds *et al.*, 1971). Therapeutic management of moderately affected anasarca fetus with diuretics is suggested, which was not feasible in the present case since the newborn was found with visceroptosis (Cunto *et al.*, 2015). In conclusion, ultrasonography aids in the diagnosis of the water puppy condition of the fetus and caesarean section is recommended for its delivery.

REFERENCES

- Cunto, M., Zambelli, D., Castagnetti, C., Linta, N. and Bini, C. (2015). Diagnosis and treatment of fetal anasarca in two English Bull Dog puppies. *Pak. Vet. J.*, 35(2): 251-253.
- Hopper, B.J., Richardson, J.L. and Lester, N.V. (2004). Spontaneous antenatal resolution of canine hydrops fetalis diagnosed by ultrasound. *J. Small Anim. Pract.* 45: 2-8.
- Hoskins, J.D. (2008). Emergency in neonatology. Proceedings of the International SCIVAC Congress. Rimini, Italy, 30 May to 1 June, 2008, Pp. 255-266.
- Ladds, P.W., Dennis, S.M. and Leipold, H.W. (1971). Lethal congenital edema in Bulldog pups. *J. Am. Vet. Med. Assoc.* 159: 81-86.
- Lumbers, E.R., Gunn, A.J., Zhang, D.Y., Wu, J.J., Maxwell, L. and Bennet, L. (2001). Nonimmune hydrops fetalis and activation of the renin-angiotensin system after asphyxia in preterm fetal sheep. *Am. J. Phys. Regul. Integr. Comp. Physiol.* 280: 1045-1051.