

# Autotransplantation of malposed mandibular right lateral incisor

Priyanka Shivanand, G. A. Babitha, Saubhik Ghosh, Shobha Prakash

Department of Periodontics, College of Dental Sciences, Davangere, Karnataka, India

**Address for correspondence:** Dr. Priyanka Shivanand, E-mail: [cooldent7@gmail.com](mailto:cooldent7@gmail.com)

## ABSTRACT

Single tooth malposition has been a problem since antiquity, and attempts have been made to correct this for quite a while. Autogenous tooth transplantation, or autotransplantation, is the surgical repositioning of a tooth from one location in the mouth to another in the same individual. Patient selection accompanied with an appropriate technique can lead to phenomenal esthetic and functional results. Here, the donor tooth was extracted, treated endodontically, and transferred to a prepared socket and splinted. On postoperative radiographic examination, the donor tooth showed no pathological changes and had no mobility associated and was well in function and esthetics.

## CLINICAL RELEVANCE TO INTERDISCIPLINARY DENTISTRY

Autotransplantation is a viable, conservative, and an economically alternative treatment to implant or extraction to position a malposed tooth/teeth.

**Key words:** Autotransplantation, esthetics, tooth replantation

## INTRODUCTION

Autogenous tooth transplantation, or autotransplantation, is the surgical movement in one individual of a vital or endodontically treated tooth from<sup>[1]</sup> its site of origin and transplanted to a surgically prepared socket.<sup>[2]</sup> Autogenous tooth transplantation was first well documented in 1954 by Hale.<sup>[3]</sup>

Orthodontic space closure and prosthetic replacement are two possible perspectives to solve single tooth malposition but can undermine esthetics, symmetry, occlusal function, or periodontal stability.<sup>[4]</sup> The transplantation is considered as an oral rehabilitation's alternative approach, of conservative character, mainly in young patients presenting a tooth structure compromised by caries or in patients with little financial conditions to perform a high-cost treatment.<sup>[5]</sup>

On tooth transplantation, main indications are to clinical cases of congenital tooth absence; traumas; atypical tooth eruption; extensive carious lesions; root resorption; endodontic treatment failures (intentional reimplantation); root fractures; periodontal disease; need for tooth extractions; and if the prosthetic treatment is not practical, due to socioeconomic reasons.<sup>[6]</sup>

Here is a clinical case of autogenous tooth transplantation of a malposed tooth of the mandibular anterior teeth that was attempted with the consent of the patient with risks and complications of the treatment explained.

## CASE REPORT

A 28-year-old systemically healthy female individual visits the OPD Department of Periodontics and

This is an open access article distributed under the terms of the Creative Commons Attribution-NonCommercial-ShareAlike 3.0 License, which allows others to remix, tweak, and build upon the work non-commercially, as long as the author is credited and the new creations are licensed under the identical terms.

**For reprints contact:** [reprints@medknow.com](mailto:reprints@medknow.com)

**How to cite this article:** Shivanand P, Babitha GA, Ghosh S, Prakash S. Autotransplantation of malposed mandibular right lateral incisor. J Interdiscip Dentistry 2016;6:71-4.

Access this article online	
Quick Response Code: 	Website: <a href="http://www.jidonline.com">www.jidonline.com</a>
	DOI: 10.4103/2229-5194.197685

Implantology, College of Dental Sciences, Davangere, with a chief complaint of spacing in the lower right front tooth region and gives no history of trauma or exfoliation of tooth.

On intraoral examination, transpositioned mandibular right lateral incisor (42) placed lingual to canine and interdental spacing between the right lower central and canine [Figure 1]. Intraoral periapical radiograph showed overlap of the tooth, with no evidence of alveolar bone loss [Figure 2].

On the recipient site, a new socket area was created with water-cooled tungsten carbide bur using slow speed [Figure 3] and the recipient site was covered with wet gauze. Lingually placed lateral incisor was carefully extracted to prevent any damage to the periodontal ligament and was placed into the recipient site to check its dimensions and occlusal interferences. Proximal slicing was performed to fit the tooth interdentally in passive form [Figure 4]. Endodontic therapy followed by apicoectomy was done of the donor tooth, to avoid any postendodontic inflammatory responses;

the extraction socket was grafted using PerioGlas™<sup>[7]</sup> and AbGel™ [Figure 5]; and a surgical hemostatic gelatin sponge and donor tooth was transferred to the modified recipient site and placed in slight infraocclusion and splinted for 2 weeks<sup>[8]</sup> on either side of the donor tooth.

The recipient and donor sites were grafted and sutured surgical pack was placed and immediate postoperative radiograph was taken [Figure 6].

The patient was advised postoperative instructions and medications and recalled after 1 week for suture removal, and periodic checkup of clinical and radiographic evaluation was done up to 6 months [Figures 7 and 8].

## DISCUSSION

Successful transplantation relies on specific requirements of the patient, donor tooth, and recipient site. The

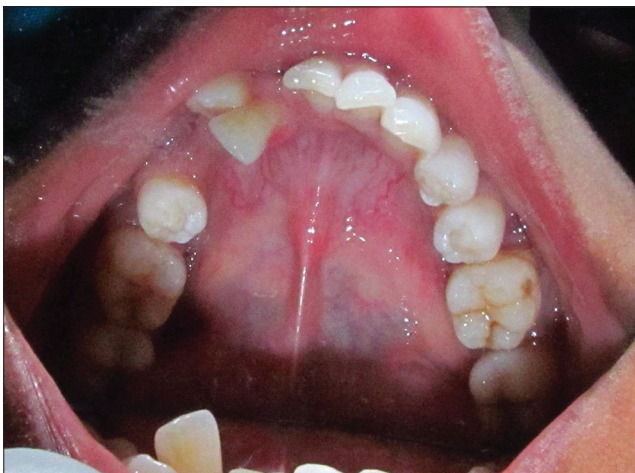


Figure 1: Preoperative view

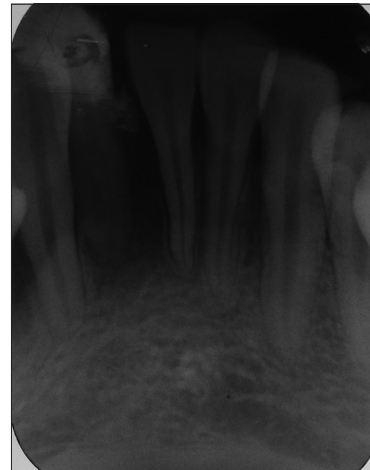

Figure 2: Preoperative radiographic view

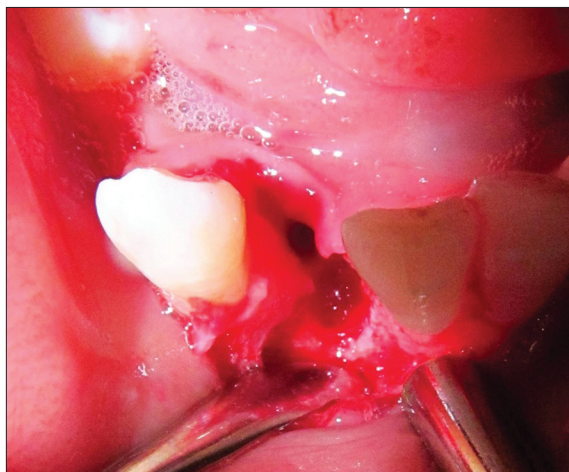


Figure 3: Surgical prepared socket

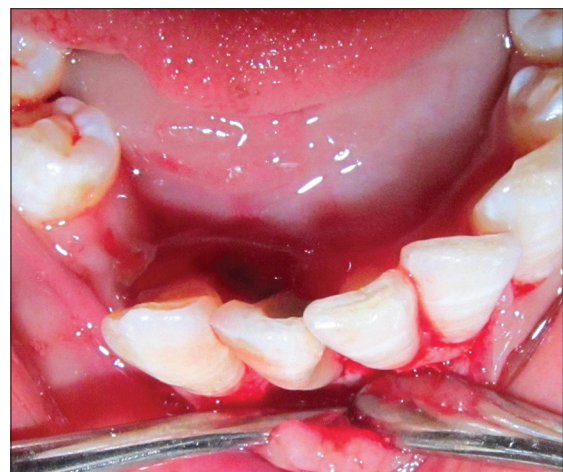


Figure 4: Tooth passively placed into socket, aligned in arch and occlusion

patient should be healthy, without systemic diseases and cooperative for follow-ups.<sup>[2]</sup>

Implants are preferable option than autotransplants because of their high success rate and practicality. However, autotransplantation is an economical option for an edentulous space or grossly decayed tooth because the procedure is performed in one stage and no prosthesis is required.<sup>[9]</sup>

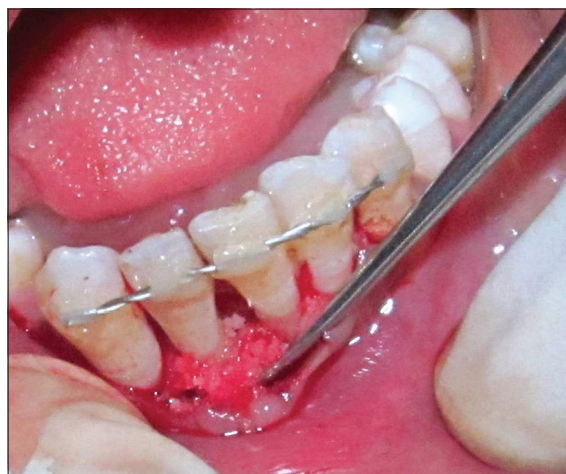A tooth with complete or near complete root formation will generally require root canal therapy, and atraumatic surgical extraction should be performed to preserve viable periodontal ligaments. Yoshino *et al.*<sup>[10]</sup> found that periodontal attachment loss (54.9%), root resorption (26.5%), dental caries (4.0%), root fracture (2.9%), and others (11.8%) are causes of autotransplanted tooth loss. Recipient site should have adequate bone support and should be free from inflammatory and infected tissue for better success

of transplantation,<sup>[4]</sup> and inflammatory root resorption can lead to failure of transplant.<sup>[11]</sup>

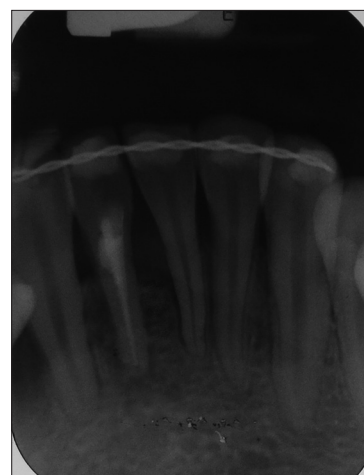Lundberg and Isaksson<sup>[12]</sup> recommended that immature donor teeth should be placed in infraocclusion and mature donor teeth in occlusion or slight infraocclusion, which was followed in the present study.

Hernandez and Cuestas-Carnero<sup>[13]</sup> stated that nonrigid splinting negatively interfere in the periodontal ligament, because it allows a certain mobility, which is a crucial stimulating factor for periodontal fibers' regeneration and favors the transplantation prognosis and use of a rigid splinting promotes the complete immobilization of the tooth, instigating tooth resorption.

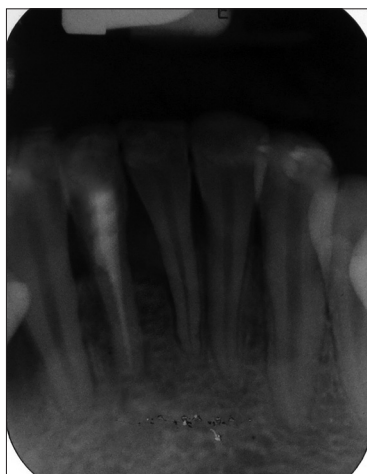Gatti *et al.*<sup>[8]</sup> on examining under Electron Scanning Microscopy, observed PerioGlas™ granules, ranging from 90 to 710 mm, implanted after tooth extraction in three patients; after 6 months bone biopsies performed in the site showed a biodegradation involving precipitation



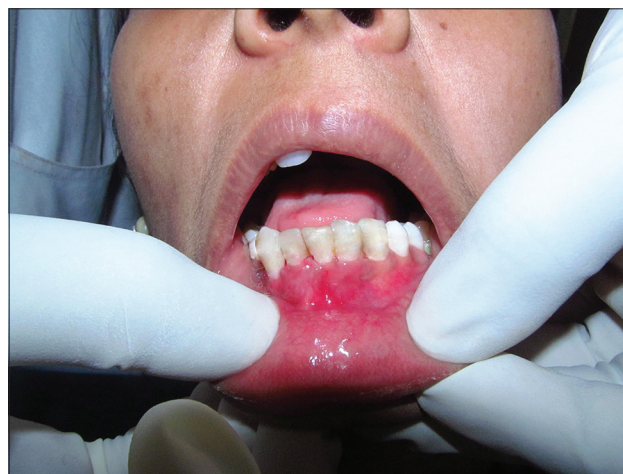**Figure 5:** PerioGlas™ and AbGel™ placed, tooth stabilized using split



**Figure 6:** Postoperative radiographic view (immediate)



**Figure 7:** Postoperative radiographic view (6 months)



**Figure 8:** Postoperative view (6 months)



of calcium phosphate that worked as a scaffold for osteoblasts colonization resulting in new bone formation and biodegradation of the glass.

Successful tooth autotransplantation helps attain improved esthetics, arch form, dentofacial development, mastication, speech, and arch integrity. In the present case, the patient was overwhelmed with the results and appreciated the outcome of the transplanted tooth. The patient compliance in all autotransplantation stages is imperative for success, to avoid complications during and after its clinical path.<sup>[14]</sup>

## CONCLUSION

Autogenous tooth transplantation can be an applicable alternative mainly in young patients with low socioeconomic conditions when well indicated, planned, and performed with surgical technique knowledge, allowing the reestablishment of the esthetics and arch form. Under given conditions, autotransplantation in combination with endodontic therapy is a viable alternative treatment option in the correction of single tooth malposition.

## Financial support and sponsorship

Nil.

## Conflicts of interest

There are no conflicts of interest.

## REFERENCES

1. Leffingwell CM. Autogenous tooth transplantation: A therapeutic alternative. *Dent Surv* 1980;56:22-3, 26.
2. Clokie CM, Yau DM, Chano L. Autogenous tooth transplantation: An alternative to dental implant placement? *J Can Dent Assoc* 2001;67:92-6.
3. Hale ML. Autogenous transplants. *Oral Surg Oral Med Oral Pathol* 1956;9:76-83.
4. Northway WM, Konigsberg S. Autogenic tooth transplantation. The "state of the art". *Am J Orthod* 1980;77:146-62.
5. Sailer HF, Pajarola GF. *Cirurgia Bucal*. Porto Alegre: Artmed; 2000.
6. Tatli U, Kırkcı M, Cam OY, Büyükyılmaz T. Autotransplantation of impacted teeth: A report of 3 cases and review of the literature. *Quintessence Int* 2009;40:589-95.
7. Gatti AM, Simonetti LA, Monari E, Guidi S, Greenspan D. Bone augmentation with bioactive glass in three cases of dental implant placement. *J Biomater Appl* 2006;20:325-39.
8. Hinckfuss SE, Messer LB. Splinting duration and periodontal outcomes for replanted avulsed teeth: A systematic review. *Dent Traumatol* 2009;25:150-7.
9. Baviz JB. Autotransplantation of teeth: A procedure that gets no respect. *Oral Surg Oral Med Oral Pathol Oral Radiol Endod* 2010;110:441.
10. Yoshino K, Kariya N, Namura D, Noji I, Mitsunashi K, Kimura H, *et al.* A retrospective survey of autotransplantation of teeth in dental clinics. *J Oral Rehabil* 2012;39:37-43.
11. Kim S, Lee SJ, Shin Y, Kim E. Vertical bone growth after autotransplantation of mature third molars: 2 case reports with long-term follow-up. *J Endod* 2015;41:1371-4.
12. Lundberg T, Isaksson S. A clinical follow-up study of 278 autotransplanted teeth. *Br J Oral Maxillofac Surg* 1996;34:181-5.
13. Hernandez SL, Cuestas-Carnero R. Autogenic tooth transplantation: A report of ten cases. *J Oral Maxillofac Surg* 1988;46:1051-5.
14. Reich PP. Autogenous transplantation of maxillary and mandibular molars. *J Oral Maxillofac Surg* 2008;66:2314-7.